

Emphyema and psoas abscess originated from pressure sore infection in uncontrolled diabetic patient

일산백병원

*김연경

Skin and soft-tissue infections are of particular concern in patients with diabetes mellitus, because skin breakdown provides a route of entry for bacteria. In addition, diabetic patients are more vulnerable to bacterial blood infections called bacteremia. We report the case of a 58-year-old undiagnosed diabetic patient diagnosed with right psoas abscess and left empyema with MSSA bacteremia originated from right buttock pressure sore infection. A 58-year-old man presented with fever and drowsy mentality. He had an alcohol dependence problem and was in hospital for controlling alcohol intake. He was found to have DM and DKA with a ketones of 3.6 mmol/L, HbA1c of 15% and C-reactive protein of 69.1 mg/dL, and had the right buttock pressure sore(4x10cm) which was graded to three. As the initial chest CT showed non-specific infection in left lung, the empirical antibiotic was used, and he was supplied with fluid replacement, electrolyte repletion and insulin. After this management, he recovered from DKA but still had persistent fever. Because serial chest x-rays were not different from initial chest x-ray, on day 10, abdomen CT was performed, which showed an abscess in right iliacus muscle (3.1x1.8x3.5cm). An 8.5F pigtail catheter drained right iliac muscle abscess with a pH 6.0 and a positive culture of MSSA that was also cultured at right pressure sore swab. On day 20, he developed chest discomfort and had persistent fever. As chest x-ray showed worsening hazy markings, we checked the chest CT, which demonstrated pneumonia with loculated left pleural effusion. An 8.5F pigtail catheter was inserted for pleural effusion drainage with a positive culture of MSSA, and urokinase irrigation was performed. On day 24, because loculated pleural effusion was not drained sufficiently, thoracoscopic guided pleurectomy and pleurolysis were performed. He made a rapid improvement and was discharged on insulin and ongoing oral antibiotics. In uncontrolled diabetic patients, severe infections, such as empyema and psoas muscle infection, are originated from skin and soft tissue infections. Therefore, better understanding of the burden of skin infections.

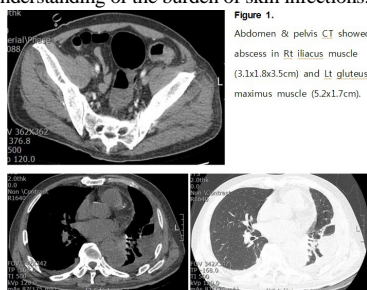


Figure 1.
Abdomen & pelvis CT showed abscess in Rt iliacus muscle (3.1x1.8x3.5cm) and Lt gluteus maximus muscle (5.2x1.7cm).

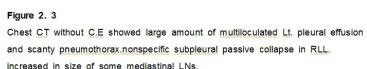


Figure 2, 3.
Chest CT without C.E showed large amount of multiloculated Lt. pleural effusion and scanty pneumothorax, nonspecific subpleural passive collapse in RLL, increased in size of some mediastinal LNs.

A case of sarcoidosis misdiagnosed as tuberculosis in South Korea

인제대학교 부산백병원

*홍성민, 양지영

Introduction: Sarcoidosis is a multisystemic inflammatory disease characterized with noncaseating granulomatous inflammation on pathologic finding. The most common sites on sarcoidosis is the lung but sarcoidosis can involve any other organs of body such as skin, eyes, heart, liver and nervous system. On the other hand, tuberculosis is an infectious disease by Mycobacterium tuberculosis and is characterized by caseating granulomatous inflammation on histology. However, it is difficult to differentiate between sarcoidosis and tuberculosis due to involvement of site and clinical features, especially in intermediate TB burden countries like South Korea. We report a case about sarcoidosis patients who were misdiagnosed to tuberculosis in the actual medical situation and given unnecessary anti-tuberculosis treatment. **Case report:** A 30-year-old woman who had been treated for tuberculosis for 18 months visited our hospital because she did not have any clinical improvement. On her chest CT, we could find cavitory lung nodules with peripheral infiltrates in upper lobes of bilateral lungs without lymph node involvement. We reviewed her medical records but there was no evidence of tuberculosis infection in the sputum study. Even 1 year after continuing TB treatment, the lesion became worse. We did bronchoscopy and percutaneous needle lung biopsy in cavitory lung lesion for inspect about tuberculosis infection or other disease. All tuberculosis related exam were negative and histologically confirmed noncaseating granulomatous inflammation and confirmed by pulmonary sarcoidosis. After using steroid treatment, her chest image and clinical symptoms rapidly improved. **Conclusion:** It is difficult to distinguish tuberculosis and sarcoidosis from diseases that may be accompanied by granulomatous inflammation in intermediate to high tuberculosis burden countries. If the results of exam about tuberculosis are not enough to diagnose or if the response to empirical anti-tuberculosis treatment is unsatisfactory, sarcoidosis should be considered among the diseases to be distinguished. So we report this case.

