

Lymphomatoid granulomatosis induced by Imatinib treatment for GIST patient

서울아산병원

*방영학, 서철원, 홍정용

Lymphomatoid granulomatosis (LYG) is angiocentric, angioinvasive, EBV-positive, B-cell lymphoproliferative disease that primarily involves the lung and skin. For pulmonary lymphomatoid granulomatosis, it is characterized that multiple pulmonary nodular lesions with lymphocytic invasion of vascular walls on biopsy. LYG may develop as a consequence of the immunosuppression induced by certain medications. There are some case reports about immunosuppressants like azathioprine, methotrexate. Herein, we are describing a case of LYG induced by imatinib treatment. A 54-year-old man had been diagnosed as gastrointestinal stromal tumor(GIST) by small bowel resection. The tumor was completely resected and started on imatinib 400mg daily. After 3 years, RLL mass was found in the follow up chest CT(Figure 1). PCNB was performed, and tissue showed an angiocentric distribution of large CD20+ atypical lymphoid cell. These are the typical histological appearances of LYG, atypical cell were shown to contain EBV (EBV; latent membrane protein and EBV-encoded RNA positivity).(Figure 2) PET-CT showed hypermetabolic mass in RLL and multiple ill-defined hypermetabolic nodules in both lungs, and there was no evidence of local tumor recurrence in small bowel anastomotic site. Bone marrow examination was performed for staging showed no infiltration. The patient took 6 cycles of R-CHOP(Rituximab, cyclophosphamide, doxorubicin, vincristine, prednisolone). And 3 cycles of IVAM(ifosfamide, cytosine, etoposide) And he took complete remission. And he had autologous transplantation. Like this case report, there were other case reports about lymphomatoid granulomatosis induced by imatinib(table). If new pulmonary nodules were detected for patients who are taking imatinib for GIST, It is easy to consider these nodules as disease progression or infectious disease. But these nodules can be lymphomatoid granulomatosis. So It is important that we should biopsy to rule out lymphomatoid granulomatosis.

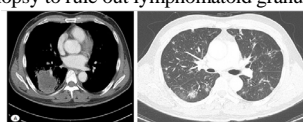


Figure1 A) Chest CT image showing low attenuated RLL mass. B) Multiple irregular nodules with surrounding subtle GGO with some internal low density portion and open bronchus sign in both lungs.

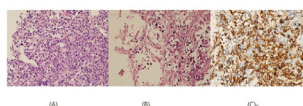


Figure2 (A) H&E stain, lymphocytic vasculitis, with infiltration of the vascular wall is seen in most cases the vascular infiltration may compromise the vascular integrity, leading to infarct-like tissue necrosis. And is mediated by chemokines induced by EBV. (B) These cells are positive for EBV by in situ hybridization with the EBER. (C) These cells are (+) for CD20.

author	GIST site	Age	sex	dose	F/U(month)	site
Yazdi AS et al.	Liver	89	F	400mg/d	3	Intrapulmonary lesions, subcutaneous nodules
Salmons N et al.	Small bowel With liver metastasis	39	M	400mg/d	30	bilateral airspace opacities and a right pleural effusion

Community-acquired pneumonia directly after anti-PD-L1 immunotherapy without immunosuppressive drugs

¹국립암센터 내과, ²국립암센터 생물약품생산실

*석지웅¹, 이영주¹, 최범규²

Background: Immune checkpoint inhibitors have been developed as promising cancer treatment in a variety of tumor types. The main adverse effect of these drugs is associated with upregulated immune system, which is called as immune-related adverse effects (irAEs). The risk of infection during immunotherapy is also mostly related to immunosuppression such as use of steroid or TNF- α inhibitor to control irAEs. Here we report a case of community-acquired bacterial pneumonia developing immediately after anti-PD-L1 antibody treatment without the use of immunosuppressant agents against irAEs. **Case:** A 62-year-old male patient visited our hospital due to cough and sputum on Dec 2017. He was diagnosed as stage IVa adenocarcinoma of lung involving right pleura. His tumor was wild type for EGFR and ALK genes and negative for PD-L1 expression. However, plasma cell free DNA test showed it had intermediate tumor mutation burden. Thus, he started to receive 1200 mg of atezolizumab every 3 weeks as 1st line treatment in Jan 2018. After 2nd cycle on Feb 27th, he suddenly presented fever, chills, cough, sputum and myalgia. His complete blood count test showed white blood cell count of 9,830/ μ L (segmented neutrophils, 78.0%; lymphocytes, 11.7%), C-reactive protein of 28.26 mg/dL, and procalcitonin of 1.30 ng/ml. A chest computed tomography (CT) showed newly-developed consolidation with ground-glass opacity in right middle and lower lobes. Respiratory virus real-time polymerase chain reaction (PCR) test using throat swab revealed positivity for Parainfluenza 2. In multiplex PCR test with sputum, Streptococcus pneumoniae and Haemophilus influenza was found positive. A sputum culture was negative. He started to be treated with cefpodoxime for pneumonia. After 2 weeks with antibiotics use, his symptom and chest-x ray showed much improvement and thus atezolizumab was resumed. The follow up chest CT after 4th cycle showed partial response(60.9% decreased from the baseline). He has continued receiving atezolizumab till July 2018 without any adverse effect. **Conclusion:** The risk to bacterial infection could be increased by transient dysregulated immune system early after the immunotherapy.

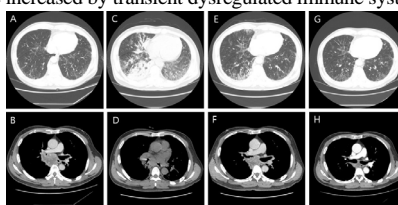


Figure 1. Chest Computed tomography (CT) images during the clinical course of the patient. (A and B) CT scan at diagnosis. There was no obvious abnormal shadow in the right lower lobe. (C and D) CT scan after two cycles of Atezolizumab (At the initial ER visit for pneumonia). Newly-developed consolidation with ground-glass opacity in right middle and lower lobes were found. (E and F) CT scan after 7days of intravenous antibiotics administration. Markedly decreased ground glass opacity in the right middle and lower lobes was found with overall decreased extent of tumor - 41.4% decreased from baseline. (G and H) CT scan after four cycles of Atezolizumab. Overall decreased extent of tumor - 60.9% decreased from baseline was found. The consolidation with ground-glass opacity in right middle and lower lobes were completely disappeared at this point.